Exhibit P-42



The Journal of General Psychology

ISSN: 0022-1309 (Print) 1940-0888 (Online) Journal homepage: https://www.tandfonline.com/loi/vgen20

Intelligence in Man after Large Removals of Cerebral Tissue: Report of Four Left Frontal Lobe Cases

D. O. Hebb

To cite this article: D. O. Hebb (1939) Intelligence in Man after Large Removals of Cerebral Tissue: Report of Four Left Frontal Lobe Cases, The Journal of General Psychology, 21:1, 73-87, DOI: 10.1080/00221309.1939.9710587

To link to this article: https://doi.org/10.1080/00221309.1939.9710587

Published online: 06 Jul 2010.

The Journal of General Psychology, 1939, **21**, 73-87.

INTELLIGENCE IN MAN AFTER LARGE REMOVALS OF CEREBRAL TISSUE: REPORT OF FOUR LEFT FRONTAL LOBE CASES*

Montreal Neurological Institute, McGill University

D. O. HEBB

Although no striking psychological changes are to be expected as the result of large surgical removals of cerebral tissue (Penfield and Evans, 1935; Jefferson, 1937), the study of such cases is still important. The lack of symptoms in the individual case does not preclude the discovery of systematic group deviations from the normal, or deviations distinguishing temporal lobe cases, for example, from frontal lobe cases. The use of standard psychological measures, and publication of test results, will eventually give data on much larger groups than could be found at any one clinic.

The four left frontal lobe cases reported here have an immediate psychological interest. The few Binet *IQ*'s which have been reported from cases of frontal lobectomy have been somewhat below normal, in the region of 80 to 90, and leave it doubtful if the low score indicates deterioration or if the original level of intelligence was low. If the original level was low, what would the effect of lobectomy be upon patients of a higher intellectual capacity? The high residual capacities found in three of the four cases, and pre- and post-operative examination made in one case, are pertinent to this question.

In this study an attempt has been made to express the amount of destruction as a fraction of the total cerebral mass, and to give an adequate account both of the extent of the lesion and of the data upon which the determination of extent depends. In human cases, for obvious reasons, control of the limits and mass of the destruction must be somewhat indirect and at the best never very satisfactory. The difficulties of localization at operation are minimized in frontal lobectomy with the turning of a wide bone flap and excision of a non-expanding lesion, but even here small variations in the angle of the plane of section will make a great difference in the amount of

*Received in the Editorial Office on June 6, 1938.
From the Montreal Neurological Institute, Montreal, Canada. Reprint No. 122.

tissue removed. With rather great unavoidable sources of error, it is the more important to have a detailed account of anatomical relations at operation, and of any conditions which affect accuracy of localization.

A. Psychological Test Material

For the determination of general intellectual level, and for the comparison of language with non-language intelligence in these patients, three tests were used: the revised Stanford Binet, Forms *L* and *M*, the Arthur Performance Scale, and the McGill revision of the Army Beta examination. The Stanford-Binet and Arthur Scales suffer perhaps from being designed primarily for use with children, and from lack of adequate standardization on adult subjects, but are nevertheless the most reliable and valid measures of general level of intelligence.

The revision of the Army Beta non-language intelligence test by Kellogg and Morton (1934) has several advantages recommending it for routine use in a neurological clinic. It is practically independent of language or pantomime instruction to the subject, making it valuable in the study of aphasia. It is extremely simple to give and to score, and supplements the Arthur Scale by presenting the subject with varied series of tasks which require sustained purposeful activity. With each test, the patient was first required to complete the "exercise" with as much help as necessary. He was then told that the following page would present more problems of the same kind, and that he was to work as fast as he could without making errors. Since the reproductions of picture absurdities in Test 3 are not always clear, the patient was told on this test not to waste time over one item if he could not see any absurdity, but to go on and return to it later if there should be enough time.

B. Case Histories

The four cases presented are from the Montreal Neurological Institute, from the services of Dr. Wilder Penfield and Dr. William V. Cone.

1. *Case I*

H.R.; 15 years, 9 months; male; right-handed. Osteomyelitis of the left frontal region of the skull led to the removal of infected bone on May 7, 1937. On June 6, 1937, Dr. Cone drained an

intracerebral abscess situated near the inferior surface of the left frontal lobe, about as far back as the beginning of the Sylvian fissure. A cylinder of normal tissue was removed to form a drainage tract, entering the dorso-lateral aspect of the lobe and passing medially and ventrally. It was 6 cm. in depth and about 2.5 cm. in diameter. The encapsulated abscess contained 50 to 75 cc. of pus, and was under enough pressure to migrate slowly to the surface after the drainage tract was opened.

The second abscess, drained by Dr. Cone on October 25, 1937, underlay the motor arm area, and produced a severe aphasia which improved rapidly after operation. Here a second cylinder of normal tissue was removed, 5 cm. in depth and about 2 cm. in diameter, entering the lobe at a point near the entrance of the first, but passing posteriorly as well as medially and ventrally. At the time of writing, seven months after operation, the patient appears clinically to have made a complete recovery.

The destruction involved in these operations is difficult to represent graphically, but the volume of normal tissue removed seems definitely to have been 45 cc. or more, in addition to the destruction caused by the abscesses themselves. Dr. Cone's opinion after the second operation was that the pathological lesions were so placed as to make any remaining tissue in the frontal pole of little functional value. An encephalogram of April 18, 1938, showed extensive atrophy of the left frontal lobe and much slighter atrophy of the right lobe. From stereoscopic examination of the encephalograms, Dr. Arthur E. Childe and Dr. Cone consider that the atrophy on the left amounts to a third or more of the frontal lobe, which is approximately the amount removed in the frontal lobectomy. Using the figures of Donaldson (1932), this would be between 6½ and 9½ per cent of the mass of the cerebrum.

The patient had entered the eighth grade in school with good marks, at the age of 14, and was considered by his teachers to be above average in intelligence. Three weeks after operation, when the speech defect was improved but still very obvious, the Stanford-Binet, Form *L, IQ* was 95; 7 weeks after operation, with few speech defects in ordinary conversation, the (*M*) *IQ* was 104; and four months after operation, when only traces of aphasia could be discovered, the (*L*) *IQ* was 110; Stanford-Binet *MA,* 16-3; Arthur Performance *MA,* above the upper limit of year standardization; score 52.50; McGill Beta, score 88.

2. *Case II*

W.B.; 33 years; male; right-handed; post-traumatic epilepsy. This case has already been reported by Penfield and Evans (1935; their Case 2). Left frontal lobectomy was carried out by Dr. Penfield in 1928 to remove cysts and a cerebral cicatrix. The operation was under local anesthesia, and a wide bone flap was turned. Seven years after operation a slight *petit mal* re-appeared, but there have been no other attacks. The removal shown in black in Figure 1 is based on a sketch made at operation.

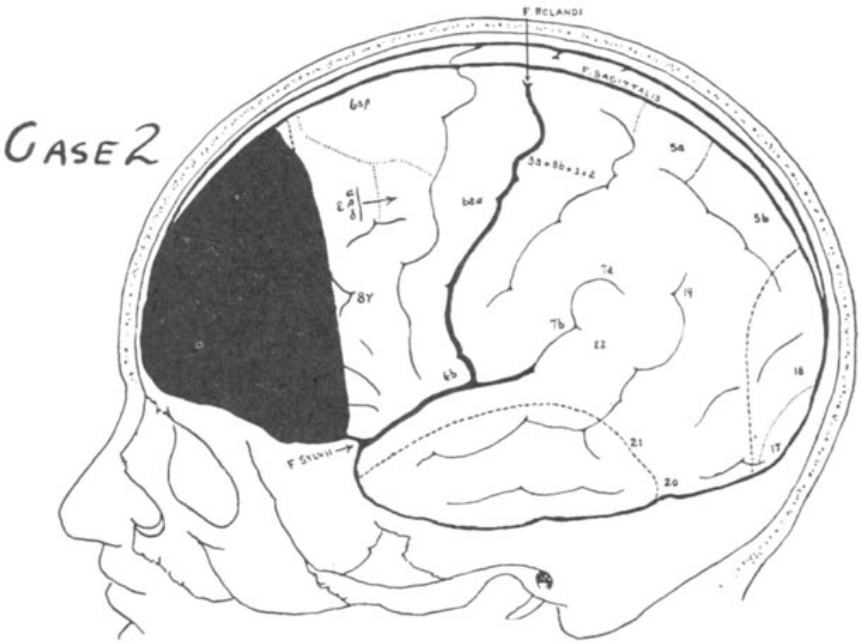

FIGURE 1
CASE 2, SHOWING THE EXTENT OF REMOVAL IN BLACK
This follows exactly the sketch made by Dr. Penfield at operation.

During early convalescence a transient aphasia occurred. Two and a half months later the patient appeared, to his parents, to be of somewhat better intelligence than before operation. This was presumably because of the arrest of the epileptic attacks, but shows at any rate that they saw no gross deterioration. The only change

is described by Penfield and Evans as a possible "lack of planned initiative."

In 1932, four years after operation, this patient was examined at the Mental Hygiene Institute of Montreal. The examination record is available through the kindness of Dr. W. T. B. Mitchell. The Stanford-Binet *MA* was 12-4, with a basal level of 8 and one success at the Average Adult level. Some features of the performance were not of a high order. The examiner noted that the answers were slow and the patient was easily fatigued. To the question, *"What should you do before beginning something important?"* there was at first no response; finally the patient said, *"I can't get it into my head,"* and could give no answer.

In 1938, five years later (nine years after operation), examination with the revised Stanford-Binet gave a rather different picture. The basal year had risen to 11, the scatter was 5 instead of 8 years, there was no sign of fatigue nor unusual slowness, and in general none of the suggestions of deterioration which marked the first examination. The *MA* was now 13-0; the re-appearance of a slight *petit mal,* absent at the time of the first examination, and the taking of two grains of phenobarbital daily would have tended to lower, not raise, the second score and makes the slight improvement in mental age more significant. Between the fourth and ninth post-operative years, then, there was possibly an improvement and certainly no deterioration. Present Stanford-Binet *IQ,* 87; Stanford-Binet *MA,* 13-0; Arthur Performance *MA,* 11-7; McGill Beta, score 64.

3. *Case III*

M.L., 20 years; male; right-handed; epileptic convulsions over a nine-year period about one per month, and recently with about four headaches a month; history of delinquency which is supposedly related to the cerebral lesion. Under general anesthesia on January 21, 1938, Dr. Penfield performed a left frontal lobectomy to remove an intracerebral cyst and calcification of surrounding tissue. Figure 2, based on a sketch made at operation, shows the extent of removal. A wide bone flap was turned, and was enlarged by rongeurs to about the same extent as the lesion shown. At the time of writing, four months after operation, there have been no further attacks.

In this case there was an opportunity to make a preoperative

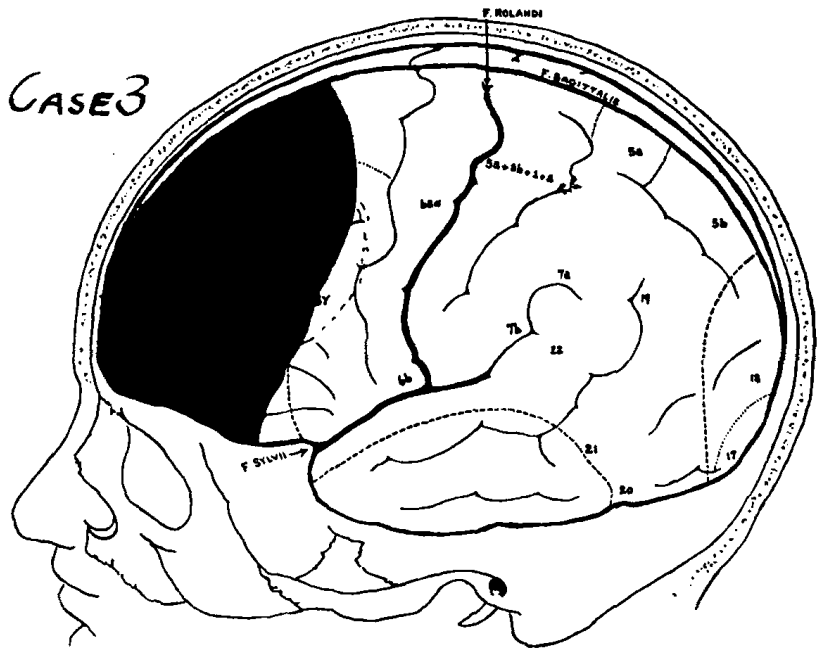

FIGURE 2

CASE 3, WITH EXTENT OF REMOVAL IN BLACK, FROM DR. PENFIELD'S OPERATION SKETCH

The greater apparent extent of the lesion is because the upper and more posterior part was superficial only, the actual amount removed probably being about the same as in Case 2.

examination in rather good circumstances. There was only a slight increase in intracranial pressure (225 mm. c.s.f.) and from the encephalogram Dr. Childe found no evidence that the cyst was producing pressure on neighboring tissue. There had been no recent headache or epileptic attack, and the subjective condition seemed very good. The pre-operative *IQ* should then be a reliable index, not of the original level, but of the level of the patient just before operation.

The operative removal consisted of one piece of tissue weighing 75 gm., plus an indeterminate amount (probably not great) removed by suction. Of the 75 gm., 55 to 60 were estimated to be neural tissue. Fifty-five grams may then be regarded as the *minimal* amount of destruction at operation; with that destroyed by pathological processes, the total must have been considerably greater. In view of

the favorable pre-operative conditions, the lack of psychological effect from such a removal was very surprising. The pre-operative Stanford-Binet, Form *L, IQ* was 124,—enough in itself almost to guarantee a good physiological condition intracranially. Examinations at 3, 3½, and 5 weeks after operation, with Stanford-Binet Forms *M, L,* and *M* respectively, gave *IQ*s of 122, 117, and 129. In the last examination there was a suggestion of practice effect, and the post-operative level is arbitrarily considered to be 123, the average of the examinations and one point below the pre-operative *IQ*. Stanford-Binet, *MA,* 17-7; Arthur Performance *MA,* 15-9 (by extrapolation: score 45.73); McGill Beta, score 79.

4. *Case IV*

M.M.; 25 years; male; right-handed; epileptic attacks for several years following the drainage of left frontal intracerebral abscesses. With the attack there was an aura of inability to speak just before

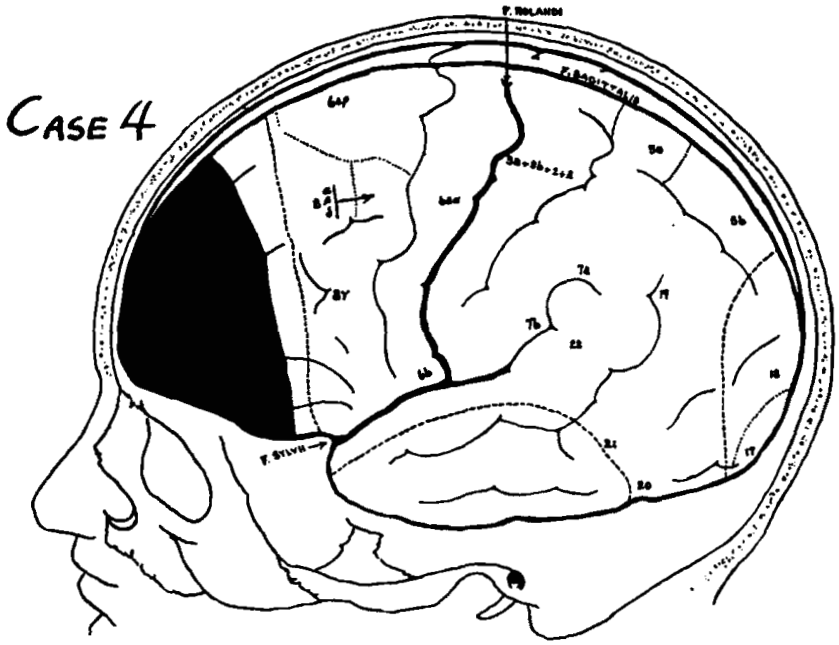

FIGURE 3

CASE 4, FROM DR. CONE'S SKETCH AT OPERATION, SHOWING THE EXTENT OF REMOVAL ON THE LATERAL SURFACE

Medially the plane of section was more posterior.

the convulsion. Dr. Cone performed a left frontal lobectomy in June, 1934, to remove scar tissue, turning a bone flap somewhat bigger than the excision shown in Figure 3. The line of section laterally was 2 cm. anterior to the Sylvian fissure, but medially was back to the genu of the corpus callosum and transected the anterior horn of the lateral ventricle. Figure 3 is based on a sketch made at operation, and shows a somewhat smaller excision than those of Figures 1 and 2. The operation notes, however, make it appear that the lesion was very nearly as great as in those cases. There has been complete cessation of attacks since operation.

Psychometric examination in 1938, four years after operation, gave an extraordinary result. The patient made no errors in the Stanford-Binet Superior Adult tests, Levels I, II, and III, with a perfect score and an *IQ* of 152. On the Arthur Scale his score was 61, on the McGill Beta 121; both practically perfect scores and well above the level of year standards. The patient, who had the reputation in high school of being "a very bright boy," is now a university senior and recently made an *A* grade in three of four examinations.

C. The Anatomical Data

The accuracy of estimates of mass must depend on the accuracy of localization at operation. How accurate are the localizations described?

It is not always realized that few cortical landmarks can be recognized by inspection at operation. The central fissure offers great difficulty, unless the operation is done under local anesthesia and electrical stimulation can be done over a fairly wide area. The posterior part of even the Sylvian fissure may be uncertain if the pia-arachnoid is not removed to allow retraction of the lobe.

Localization of the line of section in the frontal "lobectomy" is more definite than in other removals, although it still presents difficulties. The line of section passes near the level of the temporal pole, the anterior horn of the lateral ventricle and the genu of the corpus callosum, and its relation to these structures or to the lesser wing of the sphenoid bone can usually be determined. The least valuable of these in localization is the ventricle, since it may be displaced by either an expanding or a contracting lesion. With an expanding lesion, the displacement of cerebral tissue seems to

leave the corpus callosum the only reliable landmark. Dorsally, the course of the line of section must be determined by its angle with a base line or by its distance from the anterior pole of the frontal lobe, and it is here that the greatest source of error is to be expected.

The three cases of lobectomy reported above are such as to make for good localization. Although some of the data are estimates rather than actual measurements, sketches were made at operation or immediately afterward to show the relation of the lesion to the bone flap and to neighboring anatomical features. Measurements of the length and height of the excisions were also made. Since in none of these was there gross displacement of cerebral tissue, it may be considered that the localizations are as satisfactory as can be hoped for. Unfortunately, the range of unavoidable error seems to be rather great.

Eleven measures, on six formol-fixed normal brains, of the weight of the frontal lobe anterior to the Sylvian fissure, and following the angle of the line of section shown in Figure 1, gave the following percentages of total brain weight: *4.5, 4.9, 5.3, 5.5, 5.6, 5.8, 6.1, 6.2, 6.5, 7.4, 7.7,* with a mean of 6.0 and a median of 5.8 per cent. The probable limits of the fraction seem to be 4 and 8½ per cent; under operative conditions, with unavoidable sources of further error, they may arbitrarily be set at 3 and 10 per cent. Donaldson (1932) gives the proportion of cerebrum to total brain weight as .875; using this figure, the above mean becomes 6.9 per cent and the limits 3.4 and 11.6 per cent of the weight of the cerebrum. The mass removed in the present cases seems almost certainly to lie between 4½ and 10 per cent of the cerebrum.

It is evident that in Case 1 there is the least satisfactory determinations of locus and mass, although the post-operative encephalogram gives a fairly good confirmation of estimates made from the operation notes. The case is not wholly comparable with the others, in that the actual removals were from the posterior part of the frontal pole. The probability that the pathological destruction would render the residual frontal pole tissue non-functional, however, is strengthened by the degree of atrophy shown by encephalography six months after operation, and the mere fact of removal of 45 cc. of normal tissue in addition to the pathological destruction would justify the inclusion of this case with the others.

In interpreting the psychological findings, it is to be remembered that in this case there was some atrophy of the right frontal lobe as well as the left.

D. The Lack of Frontal Lobe Signs

Reported cases of frontal lobectomy have, with one or two exceptions, shown little suggestion of the frontal lobe signs described in pathological conditions. Holmes (1931) gives three kinds of mental change as the accompaniment of frontal lobe tumors: (*a*) apathy, (*b*) depression, dementia and drowsiness, or less frequently (*c*) witzelsucht and euphoria; to these may be added Goldstein's (1936) description of "loss of abstract behavior" in a case of frontal lobe atrophy. None of these effects, it seems, need be produced by surgical excision as such.

The case described by German and Fox (1934), in which severe deterioration continued after lobectomy, was one of glioblastoma; since the patient died within a year, it seems likely that there was a recurrence of the tumor (no autopsy was made) which could well account for the continued dementia. Even Brickner's (1934) case of bilateral frontal lobectomy, in which there were signs of euphoria and deterioration, had a residual intellectual capacity within normal range (Stanford-Binet *MA*s of 12-9 and 15-11 on separate examinations) and was capable on occasion of bearing himself like a normal adult. The occurrence of four *grand mal* seizures shows that there were some pathological changes in the remaining cerebral tissue, whose nature is unknown.

It is worth emphasizing again that the four cases of the present study are cases of good recovery after operation. In one only, Case 2, with an *IQ* of 87, is there clinical evidence of a continuing pathological brain condition, in the form of a *petit mal* too slight to incapacitate the patient in any way. In two cases a great time has not elapsed since operation, but the fourth has gone four years and in none of these three have clinical symptoms re-appeared.

Why, in surgical cases of complete recovery, are there so few frontal lobe signs? Jefferson (1937) has concluded that increased intracranial pressure does not sufficiently account for the pathological symptoms in cases of tumor, and that the presence of pathological tissue itself must in some way be responsible. The significance of this conclusion is worth examining.

Localization of function based on the mental changes which go with brain tumor implies that the chief effect of the lesion is a reduction of activity. With frontal lobe tumors, any deterioration not due to pressure has been taken to mean that the lost abilities or modes of behavior were inherent in the tissue destroyed; moral changes have been accounted for by supposing that a formerly active inhibition has been removed, and inhibition is therefore localized in the frontal lobe. But is there necessarily a mere loss of function? Epileptic attacks show the possibility of a change in cerebral action which is essentially neither an increment nor a decrement. There is a change in kind of activity rather than in degree, as may most clearly be seen in some types of *petit mal*. This is dysfunction of a cell mass, of course, and need not imply a corresponding dysfunction of the single cell apart from its relation to the activity of neighboring cells.

The presence of pathological tissue can thus, whether by a production of toxins or by other activity, produce a dysfunction of neighboring tissue. There is evidence suggesting that this need not always be of an epileptoid type. Electro-encephalography indicates the existence of changes in cerebral activity which are distinct in epilepsy and brain tumor. Whatever the ultimate conclusion may be concerning the significance of cerebral action-potential changes, the evidence at present points in the same direction as that from the different effects of pathological and surgical destruction. If the presence of pathological tissue is the cause of "frontal lobe signs," the signs may be the clinical manifestation of the one kind of change shown by the electro-encephalogram, as epilepsy is of the other. Such a possibility means that to study localization of function from the effect of traumatic or pathological destruction is unsafe, since one cannot know which effects are due to loss of tissue and which to the presence of pathological tissue. In the epileptic, one does not infer that convulsions appear because an inhibition of convulsions was localized at the place of the lesion, and has now been removed. There is presumably some diminution of activity, but there is also another change in the activity of tissue bordering on the lesion. The evidence adduced suggests that analogous changes occur with tumor growth, but which are manifested as apathy or euphoria or the like. If so, only from cases of good recovery after complete surgical excision of pathological tissue can safe inferences as to localization of function be made.

E. The Psychometric Data

The intelligence test scores, of Cases 3 and 4 particularly, show that a high level of ability may be retained after frontal lobectomy, and presumably that lower scores found elsewhere are due either to an originally low level or to the continued presence of pathologically affected tissue. It seems probable that the deterioration due to operation is not great. On the other hand, an intelligence test after operation can scarcely show that no deterioration has occurred, since a high post-operative level may have been originally higher.

The pre- and post-operative comparison made in Case 3 is less significant than if there had been no pathological destruction at the time of the first examination, but between the first and second examination there were 55 grams, or more, of tissue removed without effect upon the patient's *IQ*. The explanation may be that the "real" drop in *IQ* was within the error range of the Stanford-Binet, and thus not detected; or, possibly, that the arrest of epileptoid activity offset the removal of cerebral tissue. Electro-encephalographic evidence indicates the possibility of frequent sub-clinical epileptoid activity unsuspected by the patient, and this is conceivably sufficient to depress the true level of intelligence at the time of the first (pre-operative) examination.

The dominant hemisphere in all four patients appears to have been the left, since some form of speech disorder was found in three at some time during illness or convalescence, and since in none could any tendency toward left-handedness be found. The post-operative level of these patients seems then to refute the conclusion of German and Fox (1934) that frontal lobectomy upon the dominant side has a serious effect upon intelligence, and supports the conclusion of Jefferson (1937) that the left is no more important than the right unless speech areas are invaded. A related question is whether injury on the dominant side has a selective effect upon language intelligence, as suggested by Weisenburg and McBride's (1935) conclusion that lesions on the non-dominant side have a selective effect upon non-language ability. No evidence on the point is supplied by Cases 1 and 4, since their scores went above year level standards and there is no means available of comparing the two performances. In Cases 2 and 3, however, the language scores are both higher than the non-language, and from these results it seems improbable that the language intelligence is more severely affected.

When one asks what is the significance of laboratory intelligence tests in the light of Penfield and Evans' (1934) conclusion that frontal lobectomy leads to a loss of ability to plan and organize, or of planned initiative, the answer at present cannot be very certainly given. Their conclusion is not to be regarded as final, since their more striking case died after recurrence of the tumor. Their other case was of rather low intelligence (Case 2 of the present study) and had moreover been unemployed for some years. Between unemployment and prolonged hospitalization, effects somewhat similar to those described might be found in an otherwise normal individual. Such evidence as there is from the present study is opposed to the hypothesis, in that in Case 4 there is an apparently good adjustment to the demands of a college course.

It must be noted, on the other hand, that a correlation between two traits (as intelligence and practical initiative) in the normal population does not mean that the correlation holds after brain injury. The study of cases of severe deterioration is sufficient to show that pathological conditions can disturb the normal relation between abilities. A case may be cited here of a woman with incomplete removal of a large bilateral frontal glioblastoma, who retained a Superior Adult II vocabulary (Stanford-Binet), Average Adult memory for words and digits, comprehension within the normal range for verbally presented problems of various kinds, but who was quite unable to say whether it was day or night, summer or winter, whether she had had a meal recently or a lumbar puncture (the name of which she remembered, and was emphatic in her dislike of it), although she could remember the names and even the footsteps of some of the house staff; all this without stupor or depression. Such "scatter" has been regarded as indicating deterioration even when much less extreme, and indicates also that abilities formerly correlated are so no longer. Surgical excision from the frontal lobe does not seem to produce scatter in the Binet score, but may affect the relation between other abilities. The future will perhaps show whether the ability of these three young men (Cases 1, 3, and 4) to adjust themselves economically and socially is on the same plane as their intelligence test scores.

One direction of further work on the intelligence of such patients seems to be toward obtaining data from larger groups, which will permit the comparison of left frontal with right frontal lobe cases, or

temporal with occipital, and so on. A second objective is the development of tests designed for use in the adult clinical field. The occasional childishness of the test content at present available is unimportant compared to the difficulty of rating the intelligence of a patient with a sensory or motor disorder, or of making any analysis of higher-order defects betrayed by scatter in the Binet examination. Study of such patients fails to reveal any out-and-out loss of one capacity with good retention of others; instead, the problem seems always to be, what degree of ability does the patient retain? How does his ability on one type of activity compare with that on another? There is no doubt that changes are qualitative, in the sense that all capacities are not equally affected; but to give an account of the change it is necessary at present to have a means of rating various capacities independently, enabling a comparison of their levels. In other words, the failure to find in such patients a complete loss of one ability without deterioration of others means that the description of qualitative change waits upon further quantitative study.

F. Summary

Intelligence test scores are reported in four cases of extensive removal of left frontal cerebral tissue. The *IQ* in three cases was found to be above normal, and in one case in which pre- and post-operative examinations were made, no drop in *IQ* resulted from the operation.

These results are interpreted to mean that any effect of frontal lobectomy upon intelligence test performance must be relatively small. There is no evidence that excision from the dominant side has an especially great effect upon intelligence, or a greater effect upon language than upon non-language intelligence. From the lack of the classical "frontal lobe signs" after surgical removals, it is argued that the signs which have been described in pathological conditions are a clinical manifestation of a dysfunction rather than a hypofunction of the region involved. The dysfunction would be analogous to the change of cerebral action found in epilepsy, and due to the presence of pathologically affected tissue rather than to destruction of tissue alone, making unsafe any inference as to normal frontal lobe function from pathological conditions.

References

1. Brickner, R. M. An interpretation of frontal lobe function based upon the study of a case of partial bilateral frontal lobectomy. *Asso. Res. Nerv. & Ment. Dis.*, 1934, **13**, 259-351.
2. Donaldson, H. H. The brain problem—in relation to weight and form. *Amer. J. Psychiat.*, 1932, **12**, 197-214.
3. German, W. J., & Fox, J. C. Observations following unilateral lobectomies. *Asso. Res. Nerv. & Ment. Dis.*, 1934, **13**, 378-434.
4. Goldstein, K. The significance of the frontal lobes for mental performances. *J. Neur. & Psychopath.*, 1936, **17**, 27-40.
5. Holmes, G. Discussion on the mental symptoms associated with cerebral tumors. *Proc. Roy. Soc. Med.*, 1931, **24**, 997-1000.
6. Jefferson, G. Removal of right or left frontal lobes in man. *Brit. Med. J.*, 1937, No. 3995, 199-206.
7. Kellogg, C. E., & Morton, N. W. Revised Beta examination. *Person. J.*, 1934, **13**, 94-100.
8. Penfield, W., & Evans, J. The frontal lobe in man: A clinical study of maximum removals. *Brain*, 1935, **58**, 115-133.
9. Weisenburg, T., & McBride, K. E. Aphasia: A Clinical and Psychological study. New York: Macmillan, 1935.

Montreal Neurological Institute
3801 University Street
Montreal, Canada